

Clinical Immunology Review Series: An approach to the patient with angio-oedema

ARTICLES PUBLISHED IN THIS CLINICAL IMMUNOLOGY REVIEW SERIES

allergy in childhood, allergy diagnosis by use of the clinical immunology laboratory, anaphylaxis, angioedema, management of pulmonary disease in primary antibody deficiency, recurrent infections in childhood, recurrent infections in adulthood, recurrent oro-genital ulceration, recurrent superficial abscesses, SLE and Sjögren's syndrome, urticaria, vasculitis/CTD

S. Grigoriadou and H. J. Longhurst
*Barts and The London NHS Trust, Royal London
Hospital, London, UK*

Accepted for publication 7 November 2008
Correspondence: H. J. Longhurst, Barts and The
London NHS Trust, Pathology Building, 2nd
floor, Royal London Hospital, London E1 2ES,
UK.
E-mail:
hilary.longhurst@bartsandthelondon.nhs.uk

Summary

Angio-oedema is a common reason for attendance at the accident and emergency department and for referral to immunology/allergy clinics. Causative factors should always be sought, but a large proportion of patients have the idiopathic form of the disease. A minority of patients represent a diagnostic and treatment challenge. Failure to identify the more unusual causes of angio-oedema may result in life-threatening situations. Common and rare causes of angio-oedema will be discussed in this article, as well as the diagnostic and treatment pathways for the management of these patients. A comprehensive history and close monitoring of response to treatment are the most cost-effective diagnostic and treatment tools.

Keywords: angio-oedema, angiotensin converting enzyme inhibitors, C1 inhibitor

Introduction: definition

The term angio-oedema refers to localized, transient swelling of the deeper layers of the skin or mucous membranes of the upper respiratory or gastrointestinal tract. The swelling can affect any part of the body, but has a predilection for the areas of more loosely attached skin. Angio-oedema is non-pitting, erythematous or skin-coloured with ill-defined margins. A burning sensation or pain may be present but pruritus is absent. This is in contrast to urticaria (with or without angio-oedema), which is characterized by itching and wheals. This paper addresses the clinical approach to patients with isolated angio-oedema; urticaria is reviewed elsewhere in this series [1]. Oedema associated with other clinical conditions, such as venous obstruction or nephrotic syndrome, will not be discussed further here, but the clinician should be aware of the other causes that can present occasionally as 'angio-oedema'.

Pathophysiology/classification (see also Box 1)

Histamine-mediated angio-oedema

Excess histamine causes increased local blood flow, endothelial permeability and swelling resulting in angio-oedema,

urticaria and, in severe cases, anaphylaxis. In immunoglobulin E (IgE)-mediated reactions, allergen binding results in cross-linking of IgE bound on mast cells which causes mast cell degranulation and release of histamine and other mediators, notably tryptase [2]. Mast cells may also degranulate in direct response to a number of agents, notably anaesthetics, contrast medium and opiates, resulting in a non-IgE-mediated anaphylactoid reaction, which may be clinically indistinguishable from true anaphylaxis [3]. Autoantibody against the mast cell IgE receptor or mast cell-bound IgE (or basophils) is another common cause of histamine release [1].

Bradykinin-mediated angio-oedemas

Bradykinin (BK) plays a physiological role in the control of vascular tone. Kallikrein catalyses production of BK from high molecular weight kinins. Kallikrein itself is activated by a variety of mediators, including factor XII of the contact system. (Fig. 1). BK binds to receptors on the vascular endothelium. BK-1 receptors are inducible by tissue injury and BK-2 receptors are expressed constitutively. BK-2 receptor binding results in substance P release from nerve fibres leading to increased vascular permeability, and leakage of plasma into the interstitial space [4–6].

Box 1. Diagnostic Classification of angioedema.

- Allergic
- Drug-related (ACEI, NSAIDs, salicylates)
- C1 inhibitor deficiency (HAE, AAE)
- Idiopathic
- Miscellaneous causes

Other mechanisms

Excess leukotrienes resulting from inhibition of prostaglandin (especially PGE₂) production by salicylates or non-steroidal anti-inflammatory drugs may result in angioedema, in association with urticaria [7]. Rare causes include vasoactive complement components, for example in hypocomplementaemic urticarial vasculitis [1].

Hereditary angio-oedema types 1 and 2

Hereditary angio-oedema (HAE) occurs as a result of C1 inhibitor deficiency (C1 INH). Those affected are heterozygous for C1 inhibitor mutations, which result in either a truncated or abnormally folded protein with low levels of circulating C1-inh (HAE1) or normal or raised levels of a

non-functional C1-inh (HAE2). Two unusual families have been described with autosomal recessive HAE, resulting from homozygous point mutations near the active site and in the promoter region respectively [8].

C1 inhibitor exerts local anti-inflammatory effects via inhibition of factors XIIa, XIa and kallikrein in the contact system, controlling production of BK from high molecular weight kininogen. Reduced level or function of C1 INH results in overactivation of the contact system and excess local BK leading to swelling [9–13]. Patients with HAE have high plasma BK which increases at the time of an attack, with extremely high local levels at sites of swelling [10,11]. Uncontrolled consumption results in a secondary deficiency of the early classical pathway components. This may explain the increased incidence of SLE in HAE, but is probably not the direct cause of the swelling [14,15].

The HAE1 and HAE2 are indistinguishable clinically. Patients experience intermittent swellings, most commonly affecting skin, mucosae, intestinal tract or abdominal viscera (Fig. 2). Attacks are typically of slow onset, reaching maximum intensity after several hours. Following this there is a plateau phase of 1–5 days, with resolution over several hours [16,17]. Twenty-five per cent of patients report a prodromal reticulate rash, or non-specific symptoms.

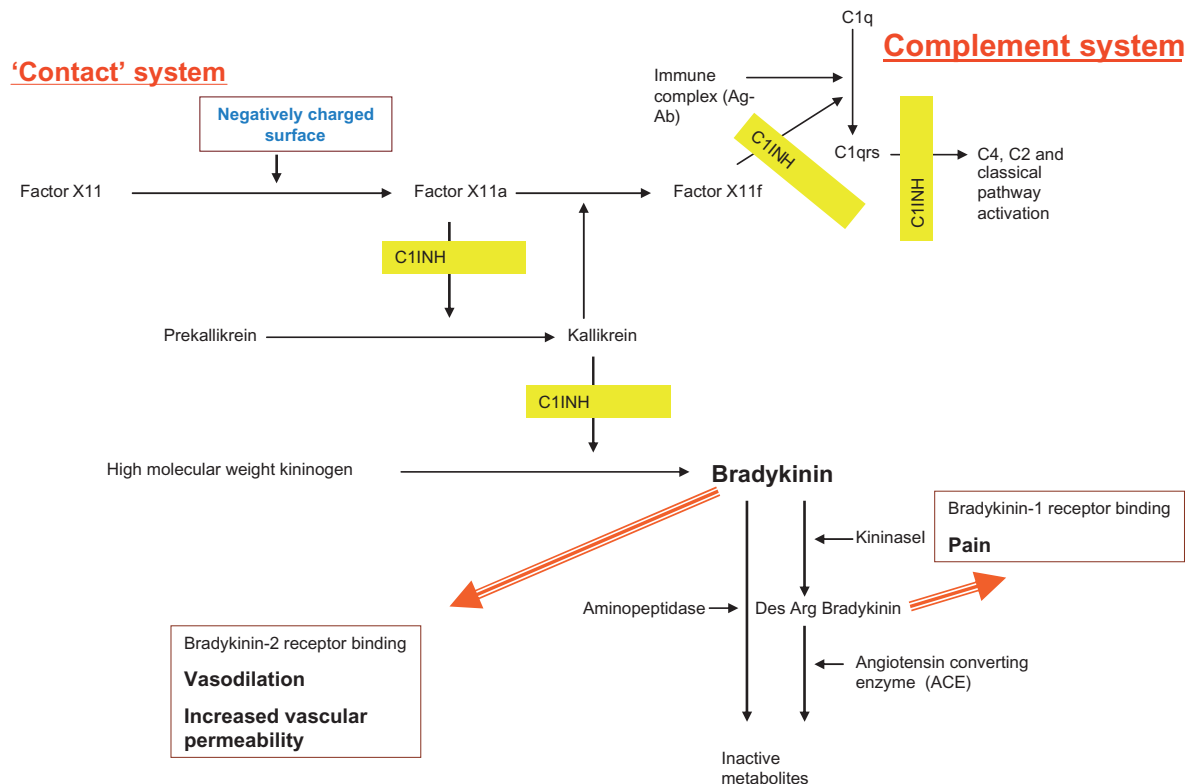


Fig. 1. Following contact activation of Factor XII by exposure to a negatively charged surface, kallikrein catalyses the production of bradykinin from high molecular weight kininogen. Contact system activation also enhances complement activation. Bradykinin binding to B2-receptors on the vascular endothelium causes local oedema. Bradykinin is metabolized by a variety of enzymes, including angiotensin converting enzyme (ACE). C1 inhibitor (C1INH) regulates the contact and classical complement pathways by inhibition at a variety of points, shown in yellow.

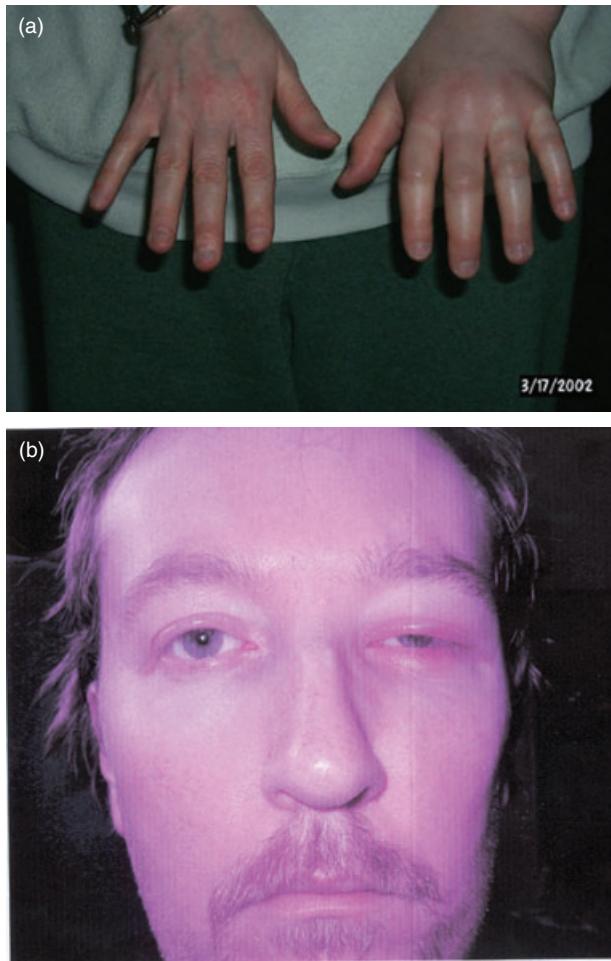


Fig. 2. (a) Swollen left hand in patient with hereditary angio-oedema (HAE). (b) Mild oedema of left eye in patient with HAE. Symptoms resolved after 500 units of C1 inhibitor given by slow intravenous injection. Delay in treatment typically results in more severe swelling requiring 1000 units of C1 inhibitor for relief.

Cutaneous swellings are diffuse, non-pruritic and usually not painful. In contrast, swellings of intra-abdominal organs are extremely painful, and associated with vomiting or diarrhoea. Hypotension, signs of bowel obstruction and ascites may be present, leading to misdiagnosis and sometimes unnecessary surgery [17–19]. Intra-oral swellings may extend to involve the larynx and cause asphyxiation, accounting for the reported mortality of up to 30%, mainly in undiagnosed patients [20–22]. Attacks are precipitated by minor trauma, particularly dental work [20], infection [23,24] or emotional stress. Angiotensin converting enzyme (ACE) inhibitors and oestrogens exacerbate HAE and are contraindicated [25].

The HAE type 3 (HAE3, HAE with normal C1 inhibitor activity)

Two groups have recently described HAE3, an autosomal dominant inherited angio-oedema without abnormalities of

complement or C1 inhibitor [26,27]. Clinical features are similar to those of HAE1 and HAE2. Orofacial involvement appears to be more common, abdominal attacks slightly less frequent, and prodromal erythema not reported [28]. HAE 3 is oestrogen-sensitive and is usually symptomatic only in women, often appearing during pregnancy or after oestrogen administration [25,29]. Symptomatic men are uncommon; angio-oedema appears later in life and is less severe [30].

In some kindreds, those affected have point mutations of the coagulation factor XII (FXII) gene [31–34]. FXII transcription is enhanced by oestrogens, explaining the female preponderance [35].

Acquired C1 inhibitor deficiency (acquired angio-oedema)

Acquired C1 inhibitor deficiency starts commonly in middle age, whereas most patients with HAE experience their first attack during childhood or adolescence. This and the lack of a family history should alert the clinician to the possibility of acquired angio-oedema (AAE). Symptoms are otherwise similar to HAE [36]. AAE is associated with lymphoproliferative disease [36,37], autoimmune disease [38–40] or less commonly vasculitis [40] or infection [24]. Lymphoproliferative disease is often indolent and may only become evident some time after the AAE diagnosis [36,37]. C1 inhibitor deficiency occurs as a result of increased consumption by paraprotein, or immune complexes (AAE type I), or direct cleavage by C1 inhibitor autoantibodies (AAE type II) [38].

Idiopathic angio-oedema

In contrast to anaphylaxis, which occurs within minutes of exposure, idiopathic angio-oedema does not have a clear relationship with any allergen and may take hours to reach maximum severity. In 40% of cases, idiopathic angio-oedema is mediated by autoantibodies which bind either to the Fcε1 of the IgE itself, or to the mast cell FcεR1 causing cross-linking and histamine release [41].

Autoimmune angio-oedema is associated strongly with urticaria, and the autoimmune nature can be demonstrated by the autologous serum test. There is an association with organ-specific autoimmune disorders, particularly of the thyroid, reviewed elsewhere in this series [1].

Eight to 11% of patients do not have urticaria and may be clinically, aetiologically and therapeutically distinct [42,43]. A review from a large specialist centre identified 254 cases of idiopathic angio-oedema in a series of 929 consecutive patients with angio-oedema without urticaria, presenting over a 10-year period [44]. The majority (86%) responded to long-term anti-histamines. Non-responders requiring treatment had complete or partial symptom control with tranexamic acid (median therapy duration 46 months). This group had increased frequency of upper airways involvement or recurrent abdominal pain.

The ACE inhibitor-related angio-oedema

Although the mechanism of ACE-inhibitors (ACEI)-related angio-oedema remains to be established; evidence to date suggests that impaired metabolism of BK is the principal mechanism of this type of angio-oedema. ACE has two functions: it inactivates BK and converts angiotensin I to angiotensin II. ACE inhibition causes angio-oedema by increasing local tissue BK. Genetic variation of other enzymes involved in the catabolism of BK or substance P, such as aminopeptidase P and dipeptidyl peptidase IV, respectively, influence susceptibility to ACEI-induced angio-oedema in specific populations [4,45–47].

The ACEI-associated angio-oedema usually affects the lips, face and tongue. The gut wall is rarely involved [48,49] with episodic abdominal pain, which may lead to unnecessary surgical interventions. Fatal cases because of laryngeal angio-oedema have been reported [50–54]. Continued use of ACEIs may lead to more severe attacks over time [55,56].

The incidence of angio-oedema in people treated with ACEIs is 0.1–6% [53,57–59]. African American origin, smoking, female gender and increasing age are associated with increased risk [59–63].

Although the risk of angio-oedema is higher in the first month, most cases occur after several months up to 10 years of initiation of therapy [53,55,56,60,64–68]. Because symptoms are not associated temporally with initiation of treatment or medication time, clinicians often fail to consider this diagnosis.

Rare causes of angio-oedema

Gleich's syndrome. Gleich's syndrome is characterized by recurrent episodes of angio-oedema and/or urticaria, fever, weight gain, eosinophilia and elevated serum IgM level [69,70]. The episodes occur every few weeks to months and can last a few months. Patients are asymptomatic between attacks. Blood eosinophilia correlates with disease activity. The disease is thought to be caused by increased levels of cytokines such as interleukin (IL)-5 and IL-6 that induce inflammation and activate eosinophils. Treatment is with low-dose corticosteroids, with interferon (IFN)- α or IL-5 antagonists in refractory cases. The prognosis is good compared with other hypereosinophilic syndromes, as there is no systemic organ involvement.

A different entity of non-episodic angio-oedema and peripheral blood eosinophilia has been described in young Japanese females [71,72]. The attack usually occurs once, can last several months and resolves spontaneously. The underlying pathogenic mechanism is similar to Gleich's syndrome.

NERDS syndrome. The association of synovial nodules, eosinophilia, rheumatism, dermatitis and swelling (NERDS) syndrome has been described recently. Serum IgE levels are

Box 2. Important clinical features in evaluation of angioedema.

- Speed of onset
- Association with urticaria/without urticaria
- Site of angioedema facial/peripheral/abdominal pain
- Precipitating factors
- Natural history of attack
- Age of first onset
- Response to treatment (antihistamines/steroids/epinephrine)
- Drug history – ACE inhibitors (AR2 antags/Salicylates & NSAIs)
- Family history
- Associated features suggesting rare angioedemas-connective tissue disease or lymphoproliferative disease symptoms

high. On histology the disease is characterized by necrotizing granulomas, non-specific vasculitis, eosinophilic infiltration and eosinophil major basic protein deposition. The course is usually benign [73].

Clarkson syndrome. Clarkson syndrome, or idiopathic capillary leak syndrome, can cause acute or chronic generalized oedema [74–76] because of rapid plasma extravasation. In 80% of cases it is associated with an IgG monoclonal paraprotein, and the attacks can be life-threatening because of renal failure, pulmonary oedema and shock. Treatment includes plasma expanders and corticosteroids.

Angio-oedema has also been described with therapeutic use of cytokines such as recombinant IL-2 and IFN- α [77,78].

Differential diagnosis/evaluation

Confirmation of clinical features and time-course are essential to the correct diagnosis, and therefore the importance of a careful history cannot be overemphasized (Box 2). Speed of onset of symptoms is very rapid in systemic anaphylaxis, occurring in most cases within minutes of exposure to an allergen. In other types of angio-oedema, sometimes labelled erroneously as anaphylaxis, symptoms take several hours to reach maximum intensity. Similarly, anaphylaxis often resolves within minutes of definitive treatment, whereas other types of angio-oedema improve over hours or days. Factors precipitating anaphylaxis are usually obvious, in contrast to other forms of angio-oedema (Table 1).

An important discriminating feature is the presence or absence of urticaria. Urticaria occurs with allergic and most idiopathic angio-oedemas [79], but not with ACE inhibitor-induced or HAE.

A history of peripheral swelling and recurrent abdominal pain should alert the clinician to the possibility of HAE or acquired C1 inhibitor deficiency. A relationship with oestrogens, either exogenous or endogenous, is typical of HAE [18,25]. Family history, and in most cases, onset in the first

Table 1. Clinical features and management of angio-oedema.

Type of angio-oedema	Anaphylaxis	Idiopathic (histamine responsive)	Idiopathic (histamine unresponsive)	HAE1 and HAE2	HAE3	AAE	ACE-inhibitor-related
Typical rate of onset	Minutes	Hours	Hours				
Precipitating factors	Usually obvious: food, drugs, insect stings	No clear relationship	Unknown	Trauma, infection, emotional stress, oestrogens, ACE inhibitors	Lymphoma, infection, autoimmunity		ACE inhibitors
Emergency treatment	Epinephrine, (antihistamines, corticosteroids, fluids)	Anti-histamines, corticosteroids, (epinephrine)	Observation and airway protection measures (plasma?)	C1 inhibitor concentrate			Observation and airway protection measures

ACE, angiotensin converting enzyme; HAE, hereditary angio-oedema.

Box 3. Rare causes of angioedema.

- Autoimmune thyroid disease
- Connective tissue disease (SLE, urticaria/vasculitis)
- Gleich's syndrome
- Clarkson syndrome
- NERDS

or second decade, make HAE more likely. However, 25% of patients with HAE have no family history of angio-oedema [80]. Salicylate, non-steroidal anti-inflammatory and opioid usage may occasionally precipitate angio-oedema in association with urticaria [42].

Features of associated disease (for example lupus) may indicate one of the less common angio-oedemas [81]. Box 3 lists the diseases that are occasionally associated with angio-oedema. Other cutaneous reactions can mimic angio-oedema, especially when symptoms are atypical. The majority of these are rare, but can occasionally be confused with angio-oedema (Box 4).

Clues to diagnosis may come from response to treatment, while bearing in mind that epinephrine in particular has a major placebo effect. Non-response to epinephrine, anti-histamines or corticosteroids is typical of ACE-associated angio-oedema or HAE. An algorithm for the diagnostic approach of a patient with recurrent angio-oedema is proposed in Fig. 3.

Investigations/laboratory tests

If anaphylaxis is suspected, serial measurements of serum mast cell tryptase should be obtained. Tryptase has a half-life of 4 h; raised levels taken 1 and 4 h after the reaction, with return to baseline after 24 h, would support a diagnosis of anaphylaxis. Skin prick testing or specific IgE antibodies, where indicated, should be deferred to convalescence.

Patients with suspected C1 inhibitor deficiency should have C3/C4 complement and C1 inhibitor level and function measured. Normal C3, low C4 and low C1 inhibitor

Box 4. Angioedema mimics.

- Facial cellulitis
- Superior vena cava syndrome
- Thyroid eye disease
- Blepharochalasis
- Systemic amyloidosis
- Dependent oedema
- Hypoproteinemia-related oedema
- Crohn's disease
- Eosinophilic fasciitis
- Acute idiopathic scrotal oedema
- Burns
- Infections (viral, parasitic)

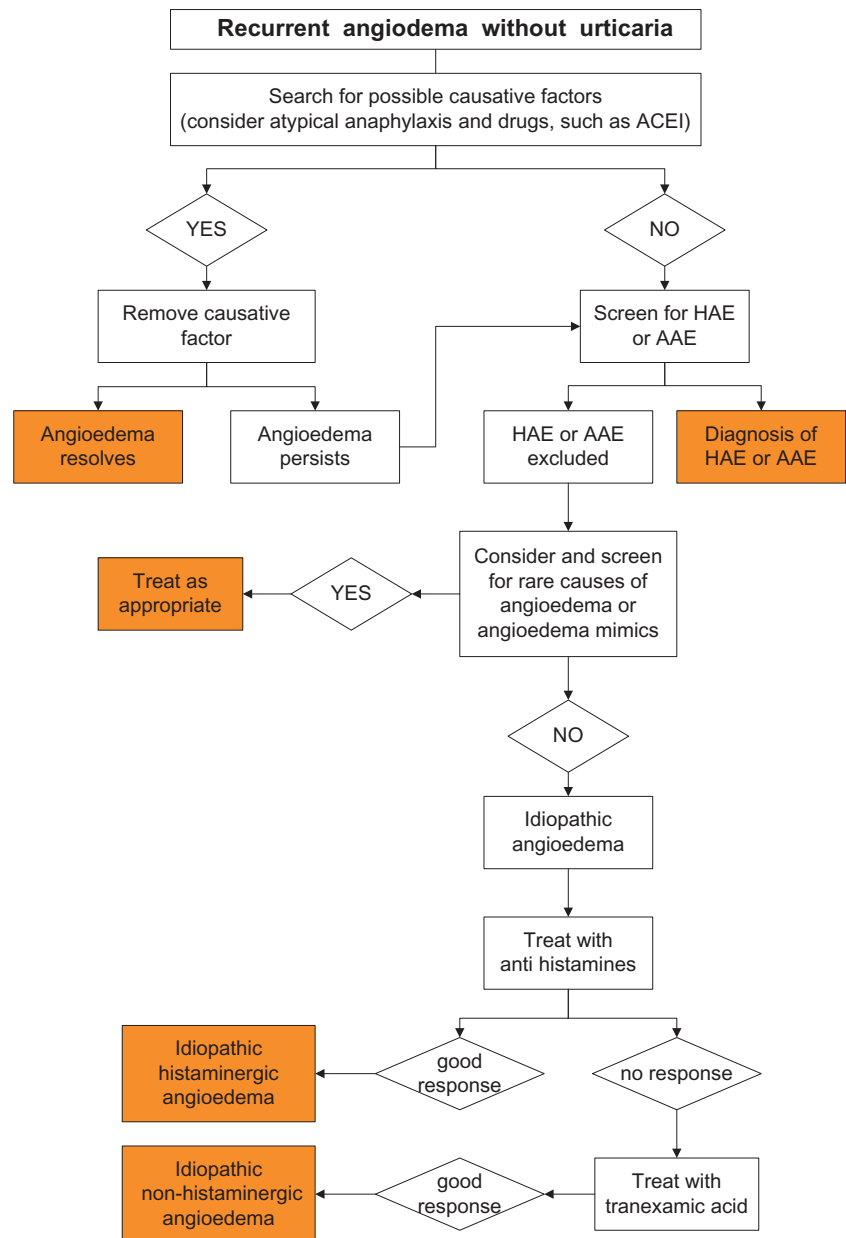


Fig. 3. Diagnostic algorithm for the patient with recurrent angioedema.

function with low C1 inhibitor level (HAE1) or normal/high C1 inhibitor level (HAE2) are diagnostic. C1q is low in acquired C1 inhibitor deficiency but normal in HAE. Of the available methods for C1 INH function, the chromogenic and enzyme-linked immunosorbent assay methods have different performance characteristics. The former may have better sensitivity whereas the latter has higher specificity, at least in some laboratories. Laboratories should generate local reference ranges, as manufacturers' reference ranges may not be optimal [82,83]. Although screening with C4 complement levels has been recommended for the diagnosis of HAE, C4 may occasionally be normal in asymptomatic individuals and therefore testing for C1 INH level and function should be performed when there is a strong clinical

suspicion of HAE [83–85]. Prolonged delay in processing or refrigeration leads to sample deterioration and should be avoided [86,87]. C1 inhibitor genotyping is useful in cases of diagnostic uncertainty, although mutations can be identified only in approximately 85% of cases [88]. HAE3 genotyping is not universally available, nor are mutations identifiable in many patients, therefore diagnosis relies largely on clinical features, family history and lack of complement abnormalities.

In cases of acquired C1 INH deficiency, lymphoproliferative disease screening should include: full blood count and film, erythrocyte sedimentation rate or plasma viscosity, liver function tests, Ig and protein electrophoresis. Where suspicion is high, urinary electrophoresis for Bence Jones protein,

peripheral blood lymphocyte immunophenotyping, bone marrow examination and computed tomography imaging of the thorax/abdomen/pelvis may be required. Rheumatoid factor, anti-nuclear antibodies, C3/C4 complement levels and C1q antibodies should be performed if connective tissue disease or urticarial vasculitis is suspected. The role of testing for anti-C1 inhibitor antibodies in the diagnosis of AAE is controversial.

Treatment

The HAE1 and HAE2

Treatment of HAE may be divided into emergency treatment of attacks, long-term prophylaxis and short-term prophylaxis to cover high-risk events such as dental work. Recently published consensus documents give guidance on optimum care [89–91].

Emergency treatment of HAE1 and HAE2

Acute swellings require treatment if involving the airway, other intra-oral sites or the face or if causing significant abdominal pain. Plasma-derived C1 inhibitor concentrates have been shown to be effective in double-blind trials for attacks at all sites [92,93]. Relief is typically evident after 30–120 min, with full resolution over about 24 h. Treatment given early in the attack gives optimum benefit [92–96]. Plasma is effective where C1 inhibitor is not available, but not recommended for planned emergency use [97,98]. High-dose fibrinolysis inhibitors, such as tranexamic acid or epsilon aminocaproic acid (EACA), have been advocated [99] but are ineffective in established attacks. Icatibant, a BK-2 receptor inhibitor, has recently been licensed for the treatment of acute HAE attacks and provides a subcutaneous alternative to C1 inhibitor [101]. Future treatment options include a recombinant C1 inhibitor (Rhucin) [100,102] and a kallikrein inhibitor, ecallantide [103,104], all of which have shown efficacy in open-label and double-blind phase II/III studies [105–107].

Prophylaxis

For patients who experience frequent or life-threatening attacks, oral prophylaxis is recommended. Methyl-testosterone or the 17 α -alkylated attenuated androgens, such as danazol [108], stanozolol [109], oxandrolone [110] and tibolone [111], reduce frequency of attacks for most patients. They probably work by increasing production of C1 INH by hepatocytes. Side effects are common and are related to the androgenic effects [98,112,113] or to the 17 α -alkylation [114].

Fibrinolysis inhibitors such as EACA and tranexamic acid are partially effective in some patients [99,115], possibly acting via reduced peripheral consumption of C1-inh.

For the minority of patients for whom oral therapies are unsuitable, C1-inh prophylaxis is indicated. This may be infused 'on demand' at the first sign of a moderate or severe attack, or prophylactically, usually every 2–7 days. Home therapy programmes have proved successful for severely affected patients or where access to emergency care is difficult [116,117].

The HAE3

There is no evidence to guide management of HAE3. Anti-histamines appear ineffective, but many patients benefit from anti-fibrinolytics or androgens. Acute attacks may respond to plasma or icatibant (unlicensed indication) (H. Longhurst, personal communication).

The AAE

Management of AAE is similar to that of other C1 inhibitor deficiencies. In contrast to HAE, anti-fibrinolytics are more likely to be effective than androgens [36]. C1-inh is used for acute attacks, although occasionally high doses are required [118]. In this situation, kallikrein or BK receptor antagonists would be a logical option. Treatment of any underlying condition may also be effective in prevention of attacks, and in some cases may normalize complement levels [36,119].

Idiopathic angio-oedema

Recent guidelines describe management of idiopathic angio-oedema with urticaria [120,121], reviewed elsewhere in this series [1]. For patients without urticaria, anti-histamines remain the first-line treatment. If these are ineffective, anti-fibrinolytics often provide relief [44]. For acute attacks, anti-histamines, corticosteroids and sometimes epinephrine are usually used. For some patients, notably those whose angio-oedema is BK-mediated, these will be ineffective [122]. Therefore patients should be observed, with measures to protect the airway if necessary, until the attack is clearly resolving. Plasma may be effective [67,123] and BK receptor or kallikrein inhibition is of interest for the future.

The ACE-inhibitor induced angio-oedema

Discontinuation of the drug results in resolution of symptoms in the majority of cases [67,124]. Although angiotensin receptor antagonists have also been reported to cause angio-oedema [125], switching to this type of drugs is usually successful [124]. C1 inhibitor concentrate and plasma have both been used successfully to treat attacks of ACE-inhibitor associated laryngeal angio-oedema [126]. Therapies currently under trial for HAE such as icatibant and ecallantide may be future options [67,106].

Acknowledgement

We would like to acknowledge Dr Gerben Bouma of the Institute of Child Health, who helped with the diagnosis flow chart.

References

- Deacock SJ. An approach to the patient with urticaria. *Clin Exp Immunol* 2008; **153**:151–61.
- Schwartz LB, Metcalfe DD, Miller JS, Earl H, Sullivan T. Tryptase levels as an indicator of mast-cell activation in systemic anaphylaxis and mastocytosis. *N Engl J Med* 1987; **316**:1622–6.
- Watkins J. Markers and mechanisms of anaphylactoid reactions. *Monogr Allergy* 1992; **30**:108–29.
- Byrd JB, Touzin K, Sile S *et al.* Dipeptidyl peptidase IV in angiotensin-converting enzyme inhibitor associated angioedema. *Hypertension* 2008; **51**:141–7.
- Campos MM, Calixto JB. Neurokinin mediation of edema and inflammation. *Neuropeptides* 2000; **34**:314–22.
- Kopp UC, Farley DM, Smith LA. Bradykinin-mediated activation of renal sensory neurons due to prostaglandin-dependent release of substance P. *Am J Physiol* 1997; **272**:R2009–16.
- Stevenson DD. Aspirin and NSAID sensitivity. *Immunol Allergy Clin North Am* 2004; **24**:491–505, vii.
- Blanch A, Roche O, Urrutia I, Gamboa P, Fontan G, Lopez-Trascasa M. First case of homozygous C1 inhibitor deficiency. *J Allergy Clin Immunol* 2006; **118**:1330–5.
- Davis AE III. The pathophysiology of hereditary angioedema. *Clin Immunol* 2005; **114**:3–9.
- Nussberger J, Cugno M, Amstutz C, Cicardi M, Pellacani A, Agostoni A. Plasma bradykinin in angio-oedema. *Lancet* 1998; **351**:1693–7.
- Nussberger J, Cugno M, Cicardi M, Agostoni A. Local bradykinin generation in hereditary angioedema. *J Allergy Clin Immunol* 1999; **104**:1321–2.
- Nussberger J, Cugno M, Cicardi M. Bradykinin-mediated angioedema. *N Engl J Med* 2002; **347**:621–2.
- Pappalardo E, Zingale LC, Terlizzi A, Zanichelli A, Folcioni A, Cicardi M. Mechanisms of C1-inhibitor deficiency. *Immunobiology* 2002; **205**:542–51.
- Khan S, Tarzi MD, Dore PC, Sewell WA, Longhurst HJ. Secondary systemic lupus erythematosus: an analysis of 4 cases of uncontrolled hereditary angioedema. *Clin Immunol* 2007; **123**:14–17.
- Zahedi R, Bissler JJ, Davis AE III, Andreadis C, Wisniewski JJ. Unique C1 inhibitor dysfunction in a kindred without angioedema. II. Identification of an Ala443→Val substitution and functional analysis of the recombinant mutant protein. *J Clin Invest* 1995; **95**:1299–305.
- Bork K, Staubach P, Eckardt AJ, Hardt J. Symptoms, course, and complications of abdominal attacks in hereditary angioedema due to C1 inhibitor deficiency. *Am J Gastroenterol* 2006; **101**:619–27.
- Bork K, Meng G, Staubach P, Hardt J. Hereditary angioedema: new findings concerning symptoms, affected organs, and course. *Am J Med* 2006; **119**:267–74.
- Agostoni A, Cicardi M. Hereditary and acquired C1-inhibitor deficiency: biological and clinical characteristics in 235 patients. *Medicine (Baltimore)* 1992; **71**:206–15.
- Farkas H, Harmat G, Kaposi PN *et al.* Ultrasonography in the diagnosis and monitoring of ascites in acute abdominal attacks of hereditary angioneurotic oedema. *Eur J Gastroenterol Hepatol* 2001; **13**:1225–30.
- Bork K, Barnstedt SE. Laryngeal edema and death by asphyxiation following tooth extraction in four patients with hereditary angioedema. *J Am Dent Assoc* 2003; **134**:1088–94.
- Bork K, Siedlecki K, Bosch S, Schopf RE, Kreuz W. Asphyxiation by laryngeal edema in patients with hereditary angioedema. *Mayo Clin Proc* 2000; **75**:349–54.
- Bork K, Hardt J, Schicketanz KH, Ressel N. Clinical studies of sudden upper airway obstruction in patients with hereditary angioedema due to C1 esterase inhibitor deficiency. *Arch Intern Med* 2003; **163**:1229–35.
- Visy B, Fust G, Bygum A *et al.* *Helicobacter pylori* infection as a triggering factor of attacks in patients with hereditary angioedema. *Helicobacter* 2007; **12**:251–7.
- Farkas H, Csepregi A, Nemesanszky E *et al.* Acquired angioedema associated with chronic hepatitis C. *J Allergy Clin Immunol* 1999; **103**:711–12.
- Bork K, Fischer B, Dewald G. Recurrent episodes of skin angioedema and severe attacks of abdominal pain induced by oral contraceptives or hormone replacement therapy. *Am J Med* 2003; **114**:294–8.
- Bork K, Barnstedt SE, Koch P, Traupe H. Hereditary angioedema with normal C1-inhibitor activity in women. *Lancet* 2000; **356**:213–17.
- Binkley KE, Davis A III. Clinical, biochemical, and genetic characterization of a novel estrogen-dependent inherited form of angioedema. *J Allergy Clin Immunol* 2000; **106**:546–50.
- Bork K, Gul D, Hardt J, Dewald G. Hereditary angioedema with normal C1 inhibitor: clinical symptoms and course. *Am J Med* 2007; **120**:987–92.
- Bork K, Dewald G. Hereditary angioedema type III, angioedema associated with angiotensin II receptor antagonists, and female sex. *Am J Med* 2004; **116**:644–5.
- Bork K, Gul D, Dewald G. Hereditary angio-oedema with normal C1 inhibitor in a family with affected women and men. *Br J Dermatol* 2006; **154**:542–5.
- Martin L, Raison-Peyron N, Nothen MM, Cichon S, Drouet C. Hereditary angioedema with normal C1 inhibitor gene in a family with affected women and men is associated with the p.Thr328Lys mutation in the F12 gene. *J Allergy Clin Immunol* 2007; **120**:975–7.
- Bouillet L, Ponard D, Rousset H, Cichon S, Drouet C. A case of hereditary angio-oedema type III presenting with C1-inhibitor cleavage and a missense mutation in the F12 gene. *Br J Dermatol* 2007; **156**:1063–5.
- Bork K. Hereditary angioedema with normal C1 inhibitor activity including hereditary angioedema with coagulation factor XII gene mutations. *Immunol Allergy Clin North Am* 2006; **26**:709–24.
- Dewald G, Bork K. Missense mutations in the coagulation factor XII (Hageman factor) gene in hereditary angioedema with normal C1 inhibitor. *Biochem Biophys Res Commun* 2006; **343**:1286–9.
- Cichon S, Martin L, Hennies HC *et al.* Increased activity of coagulation factor XII (Hageman factor) causes hereditary angioedema type III. *Am J Hum Genet* 2006; **79**:1098–104.
- Zingale LC, Castelli R, Zanichelli A, Cicardi M. Acquired deficiency of the inhibitor of the first complement component: presentation, diagnosis, course, and conventional management. *Immunol Allergy Clin North Am* 2006; **26**:669–90.

- 37 Castelli R, Deliliers DL, Zingale LC, Pogliani EM, Cicardi M. Lymphoproliferative disease and acquired C1 inhibitor deficiency. *Haematologica* 2007; **92**:716–18.
- 38 Alsenz J, Bork K, Loos M. Autoantibody-mediated acquired deficiency of C1 inhibitor. *N Engl J Med* 1987; **316**:1360–6.
- 39 Barilla-LaBarca ML, Gioffre D, Zanichelli A, Cicardi M, Atkinson JP. Acquired C1 esterase inhibitor deficiency in two patients presenting with a lupus-like syndrome and anticardiolipin antibodies. *Arthritis Rheum* 2002; **47**:223–6.
- 40 Farkas H, Szongoth M, Bely M *et al.* Angioedema due to acquired deficiency of C1-esterase inhibitor associated with leucocytoclastic vasculitis. *Acta Derm Venereol* 2001; **81**:298–300.
- 41 Asero R, Riboldi P, Tedeschi A, Cugno M, Meroni P. Chronic urticaria: a disease at a crossroad between autoimmunity and coagulation. *Autoimmun Rev* 2007; **7**:71–6.
- 42 Kozel MM, Mekkes JR, Bossuyt PM, Bos JD. Natural course of physical and chronic urticaria and angioedema in 220 patients. *J Am Acad Dermatol* 2001; **45**:387–91.
- 43 Champion RH, Roberts SO, Carpenter RG, Roger JH. Urticaria and angio-oedema. A review of 554 patients. *Br J Dermatol* 1969; **81**:588–97.
- 44 Zingale LC, Beltrami L, Zanichelli A *et al.* Angioedema without urticaria: a large clinical survey. *Can Med Assoc J* 2006; **175**:1065–70.
- 45 Adam A, Cugno M, Molinaro G, Perez M, Lepage Y, Agostoni A. Aminopeptidase P in individuals with a history of angio-oedema on ACE inhibitors. *Lancet* 2002; **359**:2088–9.
- 46 Blais C Jr, Brown JL, Rouleau NJ *et al.* Serum metabolism of bradykinin and des-Arg9-bradykinin in patients with angiotensin-converting enzyme inhibitor-associated angioedema. *Immunopharmacology* 1999; **43**:293–302.
- 47 Russell JS, Chi H, Lantry LE, Stephens RE, Ward PE. Substance P and neurokinin A metabolism by cultured human skeletal muscle myocytes and fibroblasts. *Peptides* 1996; **17**:1397–403.
- 48 Mullins RJ, Shanahan TM, Dobson RT. Visceral angioedema related to treatment with an ACE inhibitor. *Med J Aust* 1996; **165**:319–21.
- 49 Orr KK, Myers JR. Intermittent visceral edema induced by long-term enalapril administration. *Ann Pharmacother* 2004; **38**:825–7.
- 50 Dean DE, Schultz DL, Powers RH. Asphyxia due to angiotensin converting enzyme (ACE) inhibitor mediated angioedema of the tongue during the treatment of hypertensive heart disease. *J Forensic Sci* 2001; **46**:1239–43.
- 51 Jason DR. Fatal angioedema associated with captopril. *J Forensic Sci* 1992; **37**:1418–21.
- 52 Oike Y, Ogata Y, Higashi D, Matsumura T, Numata Y. Fatal angioedema associated with enalapril. *Intern Med* 1993; **32**:308–10.
- 53 Slater EE, Merrill DD, Guess HA *et al.* Clinical profile of angioedema associated with angiotensin converting-enzyme inhibition. *JAMA* 1988; **260**:967–70.
- 54 Ulmer JL, Garvey MJ. Fatal angioedema associated with lisinopril. *Ann Pharmacother* 1992; **26**:1245–6.
- 55 Agostoni A, Cicardi M. Drug-induced angioedema without urticaria. *Drug Saf* 2001; **24**:599–606.
- 56 Brown NJ, Snowden M, Griffin MR. Recurrent angiotensin-converting enzyme inhibitor – associated angioedema. *JAMA* 1997; **278**:232–3.
- 57 Cameron HA, Higgins TJ. Clinical experience with lisinopril. Observations on safety and tolerability. *J Hum Hypertens* 1989; **3** (Suppl. 1):177–86.
- 58 Sica DA. The African American Study of Kidney Disease and Hypertension (AASK) trial: what more have we learned? *J Clin Hypertens* (Greenwich) 2003; **5**:159–67.
- 59 Kostis JB, Packer M, Black HR, Schmieder R, Henry D, Levy E. Omapatrilat and enalapril in patients with hypertension: the Omapatrilat Cardiovascular Treatment vs. Enalapril (OCTAVE) trial. *Am J Hypertens* 2004; **17**:103–11.
- 60 Brown NJ, Ray WA, Snowden M, Griffin MR. Black Americans have an increased rate of angiotensin converting enzyme inhibitor-associated angioedema. *Clin Pharmacol Ther* 1996; **60**:8–13.
- 61 Gibbs CR, Lip GY, Beevers DG. Angioedema due to ACE inhibitors: increased risk in patients of African origin. *Br J Clin Pharmacol* 1999; **48**:861–5.
- 62 Lefebvre J, Murphey LJ, Hartert TV, Jiao SR, Simmons WH, Brown NJ. Dipeptidyl peptidase IV activity in patients with ACE-inhibitor-associated angioedema. *Hypertension* 2002; **39**:460–4.
- 63 Morimoto T, Gandhi TK, Fiskio JM *et al.* An evaluation of risk factors for adverse drug events associated with angiotensin-converting enzyme inhibitors. *J Eval Clin Pract* 2004; **10**:499–509.
- 64 Gabb GM, Ryan P, Wing LM, Hutchinson KA. Epidemiological study of angioedema and ACE inhibitors. *Aust N Z J Med* 1996; **26**:777–82.
- 65 Kyrmizakis DE, Papadakis CE, Liolios AD *et al.* Angiotensin-converting enzyme inhibitors and angiotensin II receptor antagonists. *Arch Otolaryngol Head Neck Surg* 2004; **130**:1416–19.
- 66 Schiller PI, Messmer SL, Haefeli WE, Schlienger RG, Bircher AJ. Angiotensin-converting enzyme inhibitor-induced angioedema: late onset, irregular course, and potential role of triggers. *Allergy* 1997; **52**:432–5.
- 67 Kostis JB, Kim HJ, Rusnak J *et al.* Incidence and characteristics of angioedema associated with enalapril. *Arch Intern Med* 2005; **165**:1637–42.
- 68 Bas M, Kojda G, Bier H, Hoffmann TK. [ACE inhibitor-induced angioedema in the head and neck region. A matter of time?]. *HNO* 2004; **52**:886–90.
- 69 Gleich GJ, Schroeter AL, Marcoux JP, Sachs MI, O'Connell EJ, Kohler PF. Episodic angioedema associated with eosinophilia. *N Engl J Med*, 1984; **310**:1621–6.
- 70 Emonet S, Kaya G, Hauser C. [Gleich's syndrome]. *Ann Dermatol Venereol* 2000; **127**:616–18.
- 71 Chikama R, Hosokawa M, Miyazawa T, Miura R, Suzuki T, Tagami H. Nonepisodic angioedema associated with eosinophilia: report of 4 cases and review of 33 young female patients reported in Japan. *Dermatology* 1998; **197**:321–5.
- 72 Shimasaki AK. [Five cases of nonepisodic angioedema with eosinophilia]. *Rinsho Ketsueki* 2001; **42**:639–43.
- 73 Butterfield JH, Leiferman KM, Gleich GJ. Nodules, eosinophilia, rheumatism, dermatitis and swelling (NERDS): a novel eosinophilic disorder. *Clin Exp Allergy* 1993; **23**:571–80.
- 74 Clarkson B, Thompson D, Horwith M, Luckey EH. Cyclical edema and shock due to increased capillary permeability. *Am J Med* 1960; **29**:193–216.
- 75 Tahirkheli NK, Greipp PR. Treatment of the systemic capillary leak syndrome with terbutaline and theophylline A case series. *Ann Intern Med* 1999; **130**:905–9.
- 76 Airaghi L, Montori D, Santambrogio L, Miadonna A, Tedeschi A. Chronic systemic capillary leak syndrome Report of a case and review of the literature. *J Intern Med* 2000; **247**:731–5.

- 77 Sundin DJ, Wolin MJ. Toxicity management in patients receiving low-dose aldesleukin therapy. *Ann Pharmacother* 1998; **32**:1344–52.
- 78 Guillot B, Blazquez L, Bessis D, Dereure O, Guilhou JJ. A prospective study of cutaneous adverse events induced by low-dose alpha-interferon treatment for malignant melanoma. *Dermatology* 2004; **208**:49–54.
- 79 Kaplan AP. Clinical practice. Chronic urticaria and angioedema. *N Engl J Med* 2002; **346**:175–9.
- 80 Tosi M. Molecular genetics of C1 inhibitor. *Immunobiology* 1998; **358**–65.
- 81 Wisniewski JJ, Baer AN, Christensen J *et al.* Hypocomplementemic urticarial vasculitis syndrome. Clinical and serologic findings in 18 patients. *Medicine* (Baltimore) 1995; **74**:24–41.
- 82 Gompels MM, Lock RJ. Laboratory testing for C1 inhibitor deficiency: a comparison of two approaches to C1 inhibitor function. *Ann Clin Biochem* 2007; **44**:75–8.
- 83 Tarzi MD, Hickey A, Forster T, Mohammadi M, Longhurst HJ. An evaluation of tests used for the diagnosis and monitoring of C1 inhibitor deficiency: normal serum C4 does not exclude hereditary angio-oedema. *Clin Exp Immunol* 2007; **149**:513–16.
- 84 Karim Y, Griffiths H, Deacock S. Normal complement C4 values do not exclude hereditary angioedema. *J Clin Pathol* 2004; **57**:213–14.
- 85 Lean-Tooke A, Stroud C, Sampson A, Spickett G. Falsely normal C4 in a case of acquired C1 esterase inhibitor deficiency. *J Clin Pathol* 2007; **60**:565–6.
- 86 Wiltshire A, Whitfield P, Wild G, Egner W. C1-esterase inhibitor functional assay degradation study. Institute of Biomedical Scientists Congress, Birmingham, September 2007.
- 87 Wagenaar-Bos IG, Drouet C, Ygoren-Pursun E *et al.* Functional C1-inhibitor diagnostics in hereditary angioedema: assay evaluation and recommendations. *J Immunol Methods* 2008; **338**:14–20.
- 88 Wagenaar-Bos IG, Hack CE. Structure and function of C1-inhibitor. *Immunol Allergy Clin North Am* 2006; **26**:615–32.
- 89 Bowen T, Cicardi M, Farkas H *et al.* Canadian 2003 International Consensus Algorithm for the Diagnosis, Therapy, and Management of Hereditary Angioedema. *J Allergy Clin Immunol* 2004; **114**:629–37.
- 90 Bowen T, Cicardi M, Bork K *et al.* Hereditary angioedema: a current state-of-the-art review, VII: Canadian Hungarian 2007 International Consensus Algorithm for the Diagnosis, Therapy, and Management of Hereditary Angioedema. *Ann Allergy Asthma Immunol* 2008; **100**:S30–S40.
- 91 Gompels MM, Lock RJ, Abinun M *et al.* C1 inhibitor deficiency: consensus document. *Clin Exp Immunol* 2005; **139**:379–94.
- 92 Kunschak M, Engl W, Maritsch F *et al.* A randomized, controlled trial to study the efficacy and safety of C1 inhibitor concentrate in treating hereditary angioedema. *Transfusion* 1998; **38**:540–9.
- 93 Waytes AT, Rosen FS, Frank MM. Treatment of hereditary angioedema with a vapor-heated C1 inhibitor concentrate. *N Engl J Med* 1996; **334**:1630–4.
- 94 Bork K. Pasteurised C1 inhibitor concentrate: pharmacology, efficacy, safety and future directions. *Expert Rev Clin Immunol* 2008; **13**–20.
- 95 Bork K, Barnstedt SE. Treatment of 193 episodes of laryngeal edema with C1 inhibitor concentrate in patients with hereditary angioedema. *Arch Intern Med* 2001; **161**:714–18.
- 96 Bork K, Meng G, Staubach P, Hardt J. Treatment with C1 inhibitor concentrate in abdominal pain attacks of patients with hereditary angioedema. *Transfusion* 2005; **45**:1774–84.
- 97 Pekdemir M, Ersel M, Aksay E, Yanturali S, Akturk A, Kiyan S. Effective treatment of hereditary angioedema with fresh frozen plasma in an emergency department. *J Emerg Med* 2007; **33**:137–9.
- 98 Longhurst HJ. Emergency treatment of acute attacks in hereditary angioedema due to C1 inhibitor deficiency: what is the evidence? *Int J Clin Pract* 2005; **59**:594–9.
- 99 Blohme G. Treatment of hereditary angioneurotic oedema with tranexamic acid A random double-blind cross-over study. *Acta Med. Scand* 1972; **192**:293–8.
- 100 Bork K, Frank J, Grundt B, Schlattmann P, Nussberger J, Kreuz W. Treatment of acute edema attacks in hereditary angioedema with a bradykinin receptor-2 antagonist (Icatibant). *J Allergy Clin Immunol* 2007; **119**:1497–503.
- 101 Choi G, Soeters MR, Farkas H *et al.* Recombinant human C1-inhibitor in the treatment of acute angioedema attacks. *Transfusion* 2007; **47**:1028–32.
- 102 Longhurst H. Rhucin, a recombinant C1 inhibitor for the treatment of hereditary angioedema and cerebral ischemia. *Curr Opin Investig Drugs* 2008; **9**:310–23.
- 103 Schneider L, Lumry W, Vegh A, Williams AH, Schmalbach T. Critical role of kallikrein in hereditary angioedema pathogenesis: a clinical trial of ecallantide, a novel kallikrein inhibitor. *J Allergy Clin Immunol* 2007; **120**:416–22.
- 104 Levy JH, O'Donnell PS. The therapeutic potential of a kallikrein inhibitor for treating hereditary angioedema. *Expert Opin Invest Drugs* 2006; **15**:1077–90.
- 105 Davis AE III. The pathophysiology of hereditary angioedema. *Clin Immunol* 2005; **114**:3–9.
- 106 Cicardi M, Zingale L, Zanichelli A, Deliliers DL. Established and new treatments for hereditary angioedema: an update. *Mol Immunol* 2007; **44**:3858–61.
- 107 Lock RJ, Gompels MM. C1-inhibitor deficiencies (hereditary angioedema): where are we with therapies? *Curr Allergy Asthma Rep* 2007; **7**:264–9.
- 108 Gelfand JA, Sherins RJ, Alling DW, Frank MM. Treatment of hereditary angioedema with danazol Reversal of clinical and biochemical abnormalities. *N Engl J Med* 1976; **295**:1444–8.
- 109 Sheffer AL, Fearon DT, Austen KF. Clinical and biochemical effects of stanozolol therapy for hereditary angioedema. *J Allergy Clin Immunol* 1981; **68**:181–7.
- 110 Barakat AJ, Castaldo AJ. Successful use of oxandrolone in the prophylaxis of hereditary angioedema: a case report. *Pediatric Asthma, Allergy and Immunology* 1999; **189**–93.
- 111 Ott HW, Mattle V, Hadziomerovic D *et al.* Treatment of hereditary angioneurotic oedema (HANE) with tibolone. *Clin Endocrinol (Oxf)* 2007; **66**:180–4.
- 112 Cicardi M, Castelli R, Zingale LC, Agostoni A. Side effects of long-term prophylaxis with attenuated androgens in hereditary angioedema: comparison of treated and untreated patients. *J Allergy Clin Immunol* 1997; **99**:194–6.
- 113 Banerji A, Sloane DE, Sheffer AL. Hereditary angioedema: a current state-of-the-art review, V: attenuated androgens for the treatment of hereditary angioedema. *Ann Allergy Asthma Immunol* 2008; **100**:S19–S22.
- 114 Bork K, Schneiders V. Danazol-induced hepatocellular adenoma in patients with hereditary angio-oedema. *J Hepatol* 2002; **36**:707–9.
- 115 Frank M, Gelfand JA, Alling DW, Sherins RJ. Epsilon aminocaproic acid for hereditary angioedema. *N Engl J Med* 1977; **296**:1235–6.

- 116 Levi M, Choi G, Picavet C, Hack CE. Self-administration of C1-inhibitor concentrate in patients with hereditary or acquired angioedema caused by C1-inhibitor deficiency. *J Allergy Clin Immunol* 2006; **117**:904–8.
- 117 Longhurst HJ, Carr S, Khair K. C1-inhibitor concentrate home therapy for hereditary angioedema: a viable, effective treatment option. *Clin Exp Immunol* 2007; **147**:11–17.
- 118 Bork K, Witzke G. Long-term prophylaxis with C1-inhibitor (C1 INH) concentrate in patients with recurrent angioedema caused by hereditary and acquired C1-inhibitor deficiency. *J Allergy Clin Immunol* 1989; **83**:677–82.
- 119 Levi M, Hack CE, van Oers MH. Rituximab-induced elimination of acquired angioedema due to C1-inhibitor deficiency. *Am J Med* 2006; **119**:e3–5.
- 120 Powell RJ, Du Toit GL, Siddique N *et al.* BSACI guidelines for the management of chronic urticaria and angio-oedema. *Clin Exp Allergy* 2007; **37**:631–50.
- 121 Grattan C, Powell S, Humphreys F. Management and diagnostic guidelines for urticaria and angio-oedema. *Br J Dermatol* 2001; **144**:708–14.
- 122 Bas M, Adams V, Suvorava T, Niehues T, Hoffmann TK, Kojda G. Nonallergic angioedema: role of bradykinin. *Allergy* 2007; **62**:842–56.
- 123 Karim MY, Masood A. Fresh-frozen plasma as a treatment for life-threatening ACE-inhibitor angioedema. *J Allergy Clin Immunol* 2002; **109**:370–1.
- 124 Cicardi M, Zingale LC, Bergamaschini L, Agostoni A. Angioedema associated with angiotensin-converting enzyme inhibitor use: outcome after switching to a different treatment. *Arch Intern Med* 2004; **164**:910–13.
- 125 Kyrmizakis DE, Papadakis CE, Liolios AD *et al.* Angiotensin-converting enzyme inhibitors and angiotensin II receptor antagonists. *Arch Otolaryngol Head Neck Surg* 2004; **130**:1416–19.
- 126 Nielsen EW, Gramstad S. Angioedema from angiotensin-converting enzyme (ACE) inhibitor treated with complement 1 (C1) inhibitor concentrate. *Acta Anaesthesiol Scand* 2006; **50**:120–2.